EM CASES SUMMARY

Prepared by Dr. Keerat Grewal, Jan 2015

Episode 58 – Commonly Missed Uncommon Orthopedic Injuries, Part 2

Drs. Ivy Cheng & Hossein Medhian

Quadriceps Tendon Rupture and The Spectrum of Quadriceps Mechanism Dysfunction

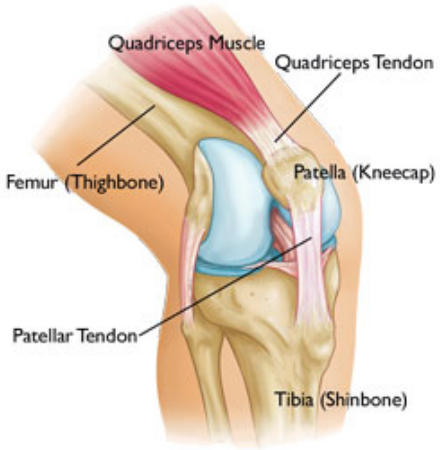

Quadriceps tendon rupture is often misdiagnosed as a simple 'knee sprain', and is not given appropriate, immediate follow-up for consideration of surgical intervention. Quadriceps tendon ruptures are more commonly seen in patients older than 40 years and are more common than patella tendon ruptures which are more commonly seen in patients under 40 years of age. Interestingly, up to 1/3 of patients present with bilateral quadriceps tendon ruptures, so comparing to the contralateral knee may be misleading.

Q: What is the spectrum of injuries in quadriceps mechanism dysfunction and how can you differentiate between them?

The spectrum of injuries includes: quadriceps tendon rupture, patellar fracture, and patellar tendon rupture.

All three injuries present with an inability to ***straight leg raise***, with pain and an effusion around the knee. In older patient, those with diabetes and patients who have recently been on Ciprofloxacin, the injury is usually minimal, and you should be suspicious of quadriceps tendon rupture. In younger patients with significant injury, be suspicious of patellar tendon ruptures. With direct injury to the knee (i.e. fall or MVC) consider a patellar fracture.

Q: What are physical exam findings in quadriceps mechanism injuries?

All three injuries present with an inability to perform a *straight leg raise*.

In a quadriceps tendon rupture, you can usually palpate a gap in the tendon above the knee. You may be able to see a suprapatellar gap (Fig 10) when inspecting the knee from the side.

Fig 10: Suprapatellar Gap

The triad of acute knee pain, inability to actively extend the knee and a suprapatellar gap clinch the diagnosis of quadriceps tendon rupture.

In a patellar fracture, patients will have tenderness over the patella. In a patellar tendon rupture, there will be a gap distally in the tendon below the patella.

Q: What are the typical x-ray findings in quadriceps tendon injuries?

Usually patients have normal x-rays. With a quadriceps tendon rupture, you *may* see ***patella Baja*** (patella rides lower than usual). In a patellar tendon rupture, you *may* see ***patella Alta*** (patella rides higher than usual).

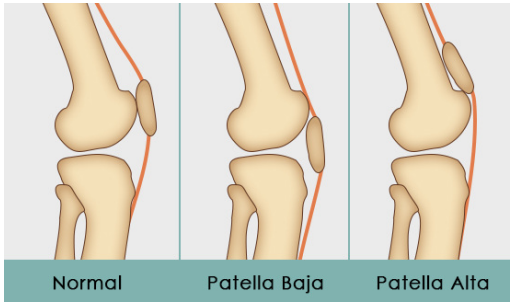

Fig 11: Patella Baja and Alta

Q: What is the ED management of patients with a suspected quadriceps tendon rupture?

These patients require a knee immobilizer (e.g a Zimmer Splint). These patients can be weight bearing, and should have orthopedics follow up within a few days for surgical consideration.

Clinical pitfall: Quadraceps mechanism injury is one of the only injuries that requires a knee immobilizer. Meniscal tears, ACL, MCL and PCL injruries are often *inappropriately* immobilized in a Zimmer splint.

Gastrocnemius Tears

Patients with calf pain and Gastrocnemius tears are often misdiagnosed as having a DVT. In fact, one small study showed that gastrocnemius tears were misattributed to DVT in 29% of patients. This confusion occurs because sometimes patients who suffer a gastrocnemius tear report a prodrome of calf tightness several days before the injury, suggesting a potential chronic predisposition. With

a good history and physical, and POCUS if you're skilled at it, needless work-ups for DVT can be avoided.

Q: What is the mechanism of injury in a gastrocneumius tear?

This injury typically occurs in sports requiring jumping or running up a hill, when a forceful push-off with the foot causes the gastrocnemius to attempt a forceful contraction against an already lengthened state. The gastrocnemius tear injury is also known as '*Tennis Leg'* or the '*Weekend Warrior'* because it usually occurs in people who are intermittently active in sport.

Q: How can a gastrocneumius tear be differentiated from a DVT?

In DVT, the affected leg may be more swollen then the other leg – this is not usually seen in a gastrocnemius tear. If there is swelling in a gastrocnemius tear, it is usually isolated to the medial aspect of the leg.

You may be able to palpate a divot between the junction of the gastrocnemius muscle and tendon in the setting of a complete tear. And finally, you may see early bruising.

Q: What are key physical exam findings in a gastrocnemius tear?

Patients will have tenderness of the entire medial gastrocnemius muscle, but will be more painful at the medial musculotendinous junction. You may be able to see a visible defect in the medial aspect of the gastrocnemius or palpate a gap in the muscle.

Perform a *Calf Raise Test* (seeFig 12), where the patient in a standing position plantarflexes one ankle so that they stand up on their tip-toes with one leg. In an Achilles tendon rupture, patients will not be able to perform this test. In a gastrocnemius tear, this test will reproduce the pain, but patients can partially complete the test.

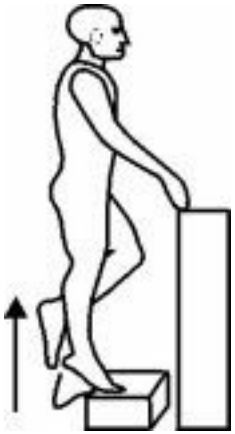

Fig 12: Calf Raise Test

Q: What is the role of imaging for a gastrocnemius tear?

X-rays have no value. A non-urgent ultrasound, while it has not been studied in any large RCTs, can be considered as an outpatient, or a POCUS, if you have the necessary skills. It is important in your request for an ultrasound, to ask the radiologist to look for a gastrocnemius tear in particular.

Q: What is the ED management for patients with a gastrocnemius tear?

Conservative management with 'RICE' (Rest, Ice Compression & Elevation) and early weight bearing as tolerated is the treatment of choice. Early physiotherapy is important, as well as explaining to the sportsperson that it may take 3-4 months before they are back to full participation.

Consider an *ankle stirrup or brace* in a position of maximal tolerable dorsiflexion for patients who are experiencing severe pain with minimal ankle ROM, as studies have shown an increased rate of healing with ankle bracing.

Key References

1. Yilmaz, C, Orgenc, Y, Ergenc, R, & Erkan, N. 2008. Rupture of the medial gastrocnemius muscle during namaz praying: An unusual cause of tennis leg. Comput Med Imaging Graph, 32(8): 728-31. Abstract available at: http://www.ncbi.nlm.nih.gov/pubmed/18963800